

Manufacturer

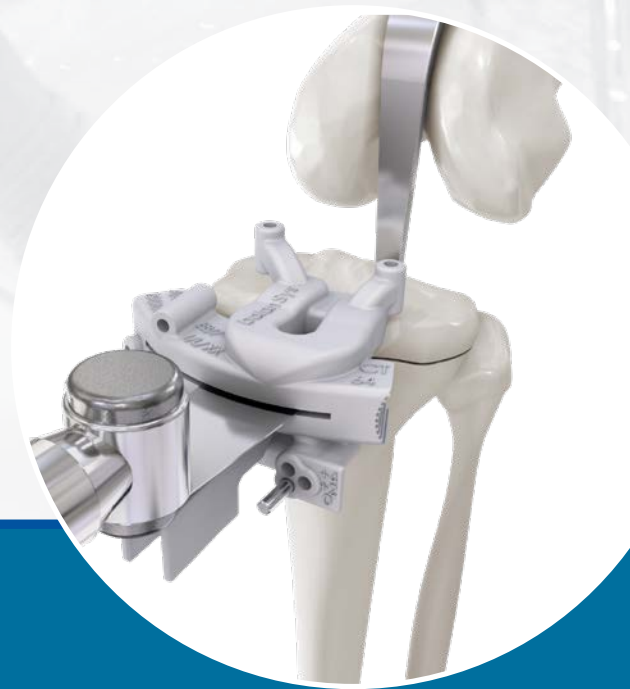

Distributed by



**Supplement to surgical technique
balanSys BICONDYLAR SMarT**

**SuMisura
for balanSys BICONDYLAR**



For healthcare professional use only. The i illustrated image does not represent a connection between the use of the medical device described, nor its performance.

Patient specific instruments

*Building on our heritage
Moving technology forward
Step by step with our clinical partners
Towards a goal of preserving mobility*

Preservation in motion

As a Swiss company, Mathys is committed to this guiding principle and pursues a product portfolio with the goal of further developing traditional philosophies with respect to materials or design in order to address existing clinical challenges. This is reflected in our imagery: traditional Swiss activities in conjunction with continuously evolving sporting equipment.

Table of contents

1. Introduction	4
2. Preoperative planning	4
3. General information	5
3.1 SuMisura cutting guides and bone models	5
3.2 Personalized data	6
3.3 Positioning and support	8
3.4 Osteophytes	8
3.5 Cartilage removal	9
3.6 Sawing	9
3.7 Tibia-first or femur-first technique	9
3.8 CT or MRI cutting guides	10
4. Access	10
5. Surgical technique	11
5.1 Tibia resection	11
5.2 Femur resection	14
5.3 Checking the extension gap	19
5.4 Secondary resection (optional)	20
6. Finalizing	22
7. Addendum on MRI cutting blocks	22
8. Instruments	23

Remark

Please make yourself familiar with the handling of the instruments, the product-related surgical technique and the warnings, the safety notes and the recommendations of the instruction leaflet before using an implant marketed by Mathys Ltd Bettlach. Make use of the Mathys user training and proceed according to the recommended surgical technique.

1. Introduction

The patient specific instruments SuMisura for balanSys BICONDYLAR represent an alternative to the standard implantation instruments for knee joint replacements. Incorporating them into the standard surgical technique greatly reduces the number of instruments to be used, as well as the number of surgical steps. In addition, no intramedullary alignment is necessary for distal femur resection, with the result that less invasive bone procedures can be used.

This surgical technique comprises instructions for integration of the tibia and femur cutting guides SuMisura for balanSys BICONDYLAR into the existing knee surgery technique balanSys BICONDYLAR SMaT with the corresponding instruments. Since the standard instruments are required in the steps following the use of the SuMisura cutting guides, the surgeon must be familiar with the entire surgical technique balanSys BICONDYLAR SMaT and with the correct use of all the standard instruments.

The surgical steps for the complete knee joint replacement are to be taken from the favored surgical technique balanSys BICONDYLAR SMaT.

2. Preoperative planning

The preoperative planning with SuMisura for balanSys BICONDYLAR is performed on the basis of CT or MRI imaging. Web-based planning software is available at www.onefit-medical.com.

Training is necessary to use this password-protected 3D knee planning software. Only surgeons trained in the use of the software are granted access. A detailed software manual is available upon request.

Whole-leg radiography is not required, because the leg axis is derived from the CT and MRI data.

We recommend the following conventional radiography status for support of the surgery:

- Knee with the patient standing on one leg, a. p.
- Knee laterally in 90° flexion
- Patella axially

3. General information

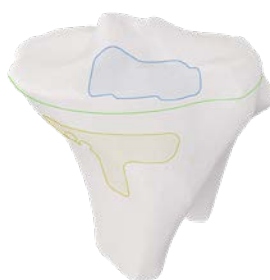3.1 SuMisura CT cutting guides and bone models




Tibia

Cutting guides



Bone models



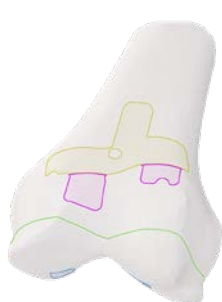-  T-bar on anterior tibia wall
-  Support feet on anterior tibia edge
-  Resection plane





Femur – central variant

Cutting guides



Bone models



-  T-bar on trochlear process
-  Support feet on trochlear osteophytes
-  Support feet in joint surface
-  Resection plane





Femur – edge variant

Cutting guides



Bone models



-  T-bar on trochlear process
-  Support feet on trochlear osteophytes
-  Support feet at edge of joint surface
-  Resection plane

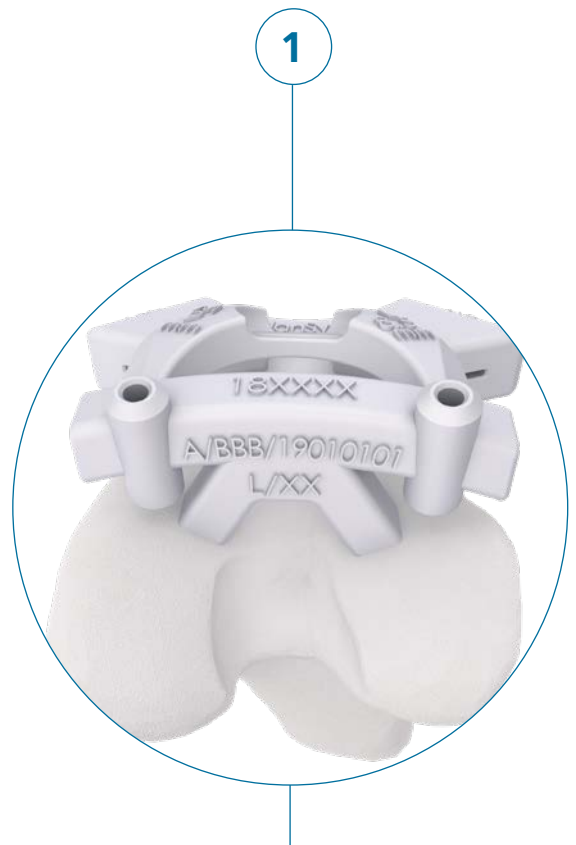Remark

The SuMisura femur cutting guide is available in two variants. They differ in terms of their support feet, which are placed either in the joint surface (femur cutting guide – central variant) or at the edge of the joint surface (femur cutting guide – edge variant) – depending on the user's wish. If during planning with the central variant it is noted that the resection plane would interfere with the support feet, the edge variant is proposed by the planner as an alternative option.

3.2 Personalized data

The following data are marked on the SuMisura cutting guides:

1	A/BBB	Patient's initials (first and last name)
	7°	Posterior slope
	19010101	Patient's date of birth (YYYYMMDD)
	R	Side: right or left
	XX	Surgeon's initials (first and last name)
2	Imaging method: CT or MRI	
3	Implant size tibia/femur	
4	Reference and LOT number	
5	Implant flexion/extension in °	
6	Varus/valgus angle in °	
7	Medial distal femur resection in mm	
8	Lateral distal femur resection in mm	

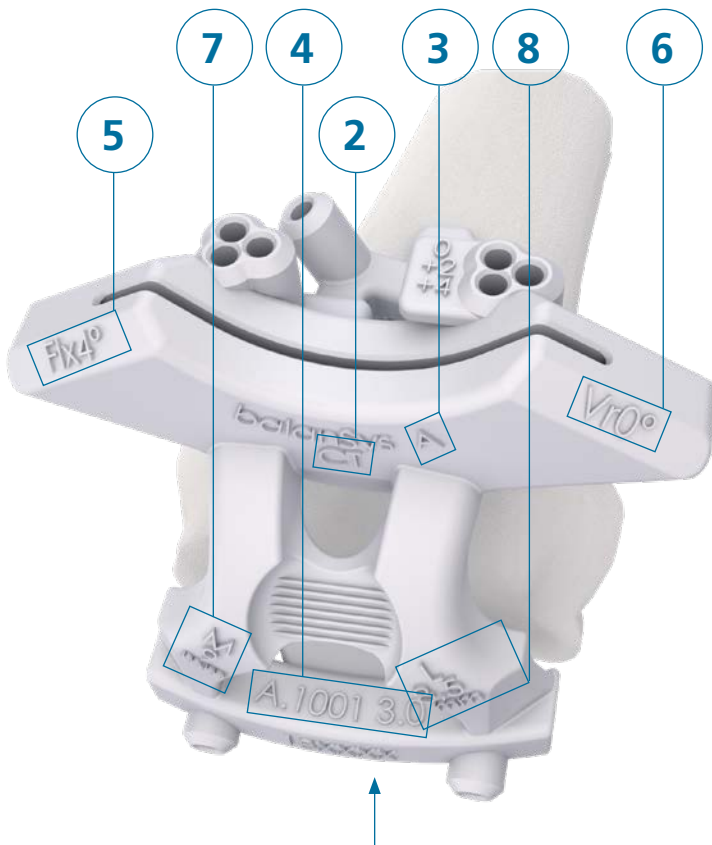
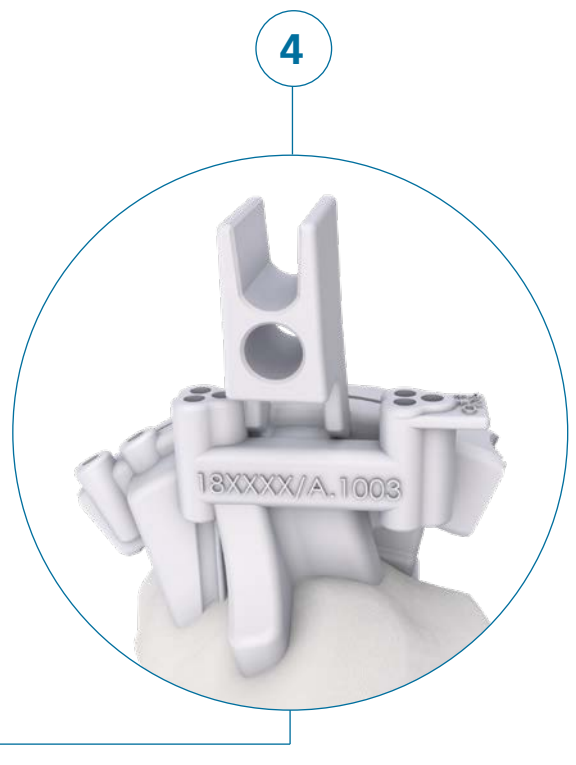
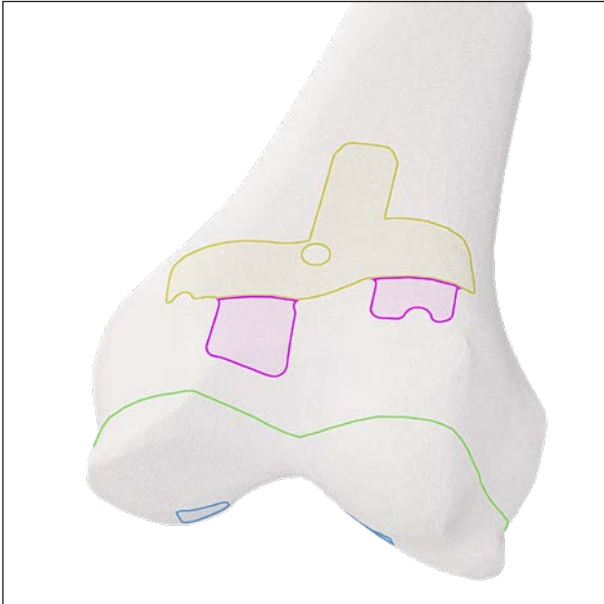




Fig. 1



Fig. 2

3.3 Positioning and support

The T-bars of the tibia and femur cutting guides rest on cartilage-free, genuine bone. The arms of the T-bars give the cutting guides optimal support on this base.

With their exact resting position on osteophyte edges and in free joint surfaces, the support feet define the precise position of the cutting guides.

In the region of the osteophytes, gaps may occur between the support feet and the bearing surfaces on the bone. This is due to the 3D modelling of the bone. It is important for the bony osteophyte edge to rest exactly in the deepest line of the bearing surface of the support foot. Feet resting on flat joint surfaces must have contact with their entire surfaces. The same applies to the arms of the T-bars. These must also rest on the genuine bone over their entire extent.

Positioning of the cutting guide is a matter of millimeter accuracy. Exact positioning of the T-bar and the feet in the joint surfaces defines the important frontal and sagittal planes.

If differences between model and reality occur in the region of the osteophytes, precise placement of the T-bar helps in finding the correct position of the cutting guide.

3.4 Osteophytes

Osteophytes must not be damaged during access. They are used for precise positioning of the cutting guide. The osteophytes are removed only after the resections with the SuMisura cutting guide have been performed, preferably before placement of the trial prosthesis.

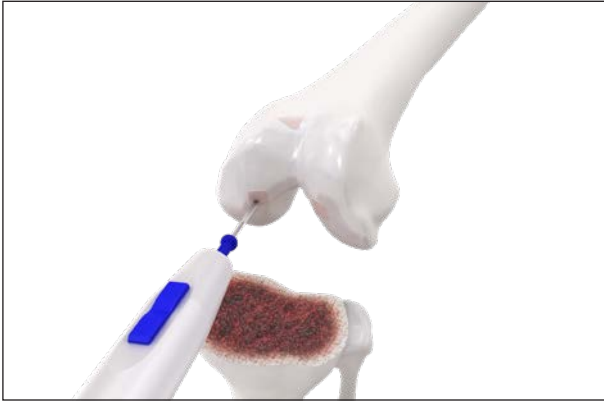


Fig. 3

3.5 Cartilage removal

Cartilage removal can be performed with the electrocautery blade. Alternatively, this is also possible with a curette energized with an electrocautery. The toxic smoke thereby generated should be removed by suction as it is poisonous.

The bony core of osteophytes may be very thin. Too long and intensive application of an electrocautery blade can burn the bone and thereby destroy the important reference. Mechanical cartilage removal instruments must also be used with caution. The edges of the osteophytes can easily break off.

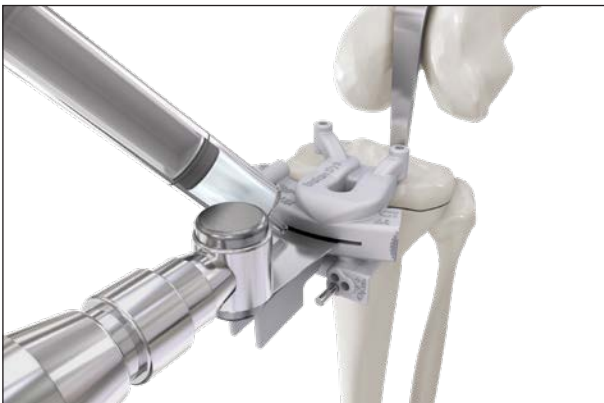

Fig. 4

3.6 Sawing

All resections must be performed using the SuMisura cutting blocks with a 1.27 mm saw blade.

Moisten the sawing slit of the cutting guide before introducing the saw blade. To reduce the heat and the risk of osteonecrosis, it is recommended to cool the saw blades during sawing.

Put the saw into oscillation before making contact with the cortical bone. On first contact with the cortical bone, excessive axial pressure should be avoided to rule out directional errors when starting the resection.

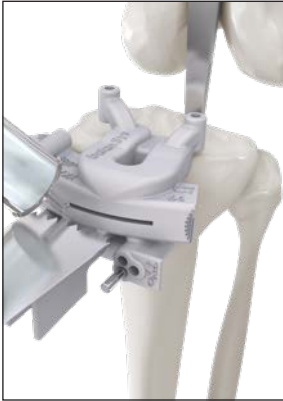

Fig. 5



Fig. 6



3.7 Tibia-first or femur-first technique

Tibia-first as well as femur-first surgeries can be performed with SuMisura.

3.8 CT or MRI cutting guides

The following surgical procedure only illustrates the use of the CT-based SuMisura cutting guide. Differences in the handling of the MRI-based cutting guides are explained in Point 7 Addendum on MRI cutting blocks on Page 22.

4. Access

SuMisura cutting guides are applied via a medial parapatellar access. Alternative subvastus accesses can be used only if sufficient exposure of the anterior medial head of the tibia and the genu bone above the trochlea can be achieved. SuMisura cutting guides are not suitable for lateral accesses.

5. Surgical technique

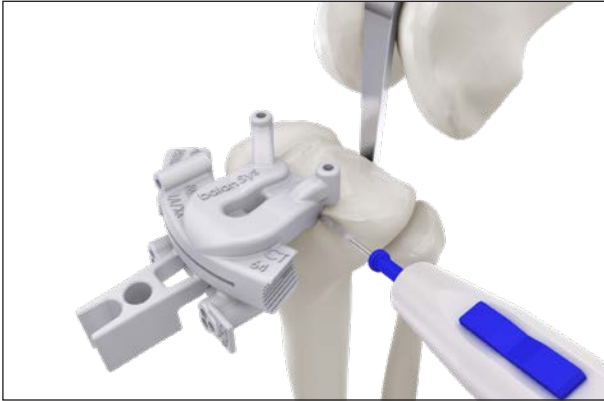

Fig. 7

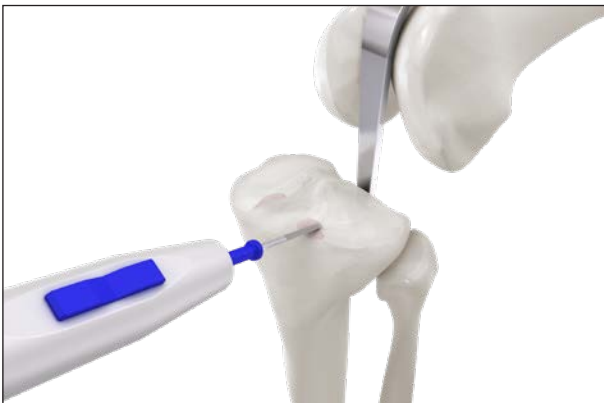


Fig. 8

5.1 Tibia resection

Positioning of the knee in 90° flexion, temporary placement of the SuMisura tibia cutting guide. The provisional position of the T-bar and the support feet is marked with an electrocautery.

Careful and precise placement of the cutting blocks is of utmost importance. Only this guarantees a correct tibia slope, correct flexion/extension of the femur component and correct tibial and femoral axial alignment.

Remark

Several sites of the osteophyte are used as reference for correct positioning of the tibia cutting guide, and the osteophytes may be removed only when the resection has been performed.

Remark

The tissue of the medial longitudinal retinaculum should be separated from the tibia in the antero-medial region using a blade. The insertion of the anterior cruciate ligament must be completely removed up to the insertion on the intercondylar eminence. It should be ensured that the patellar ligament and the tissue of the medial longitudinal retinaculum cannot compromise the position of the cutting guide.

Cartilage removal and exposure of the marked bearing surfaces of the support feet and the T-bar. The position of the cutting guide and the extent of the bearing surfaces may change after cartilage removal.

Until the final positioning of the cutting guide, in many cases several additional cleanings of the bearing surfaces are necessary, followed by a check with the cutting guide in place.

When the bearing surfaces of the T-bar and support feet are no longer compromised by soft tissue or cartilage, fine cleaning of the bearing surfaces with a wet compress is to be performed.

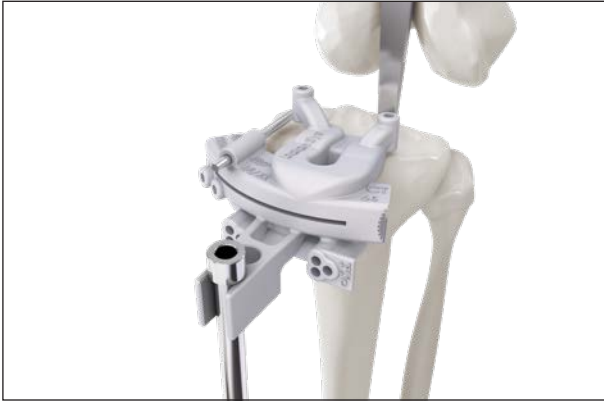

Fig. 9

Positioning of the tibia cutting guide on the prepared bearing surfaces

Exact placement on clean bearing surfaces is indicated by snapping into place. The cutting guide no longer moves from its position even when pushed.

By placement of the extramedullary alignment rod, the tibial varus/valgus axis should be checked before fixation.

Check the correct position of the cutting guide means of a pin in the pin guide above the medial compartment. The pin represents the natural tibia slope and should therefore run parallel to it.

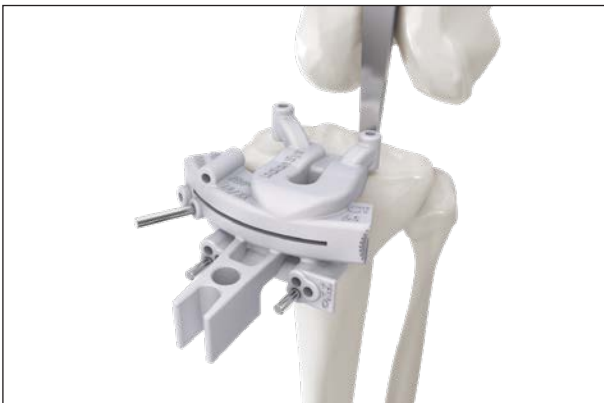

Fig. 10

As soon as the tibia cutting guide is correctly aligned, fixation is performed with two parallel pins in position «0» and with an oblique pin.

Do not displace the cutting guide when introducing the pin.

Remark

To prevent unintentional moving of the cutting guide when inserting the pins, the holes must always be pre-drilled with a 3.2 mm drill bit, or special drilling pins with a sharp tip and thread tap should be used. In either method, axially correct drilling is to be ensured.

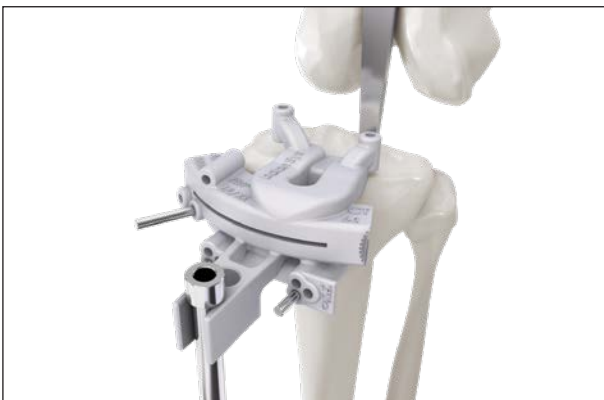

Fig. 11

After final fixation, the correct position of the cutting guide is checked again.

1. The correct leg axis (frontal plane) is checked with the extramedullary alignment rod.

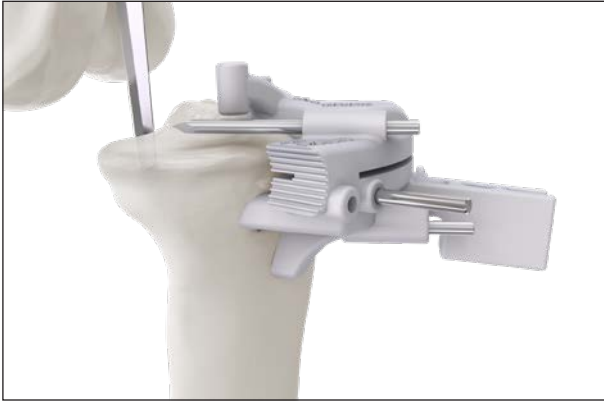

Fig. 12

2. The correct position of the cutting guide is checked with a pin in the pin guide over the medial compartment. The pin represents the patient's individual tibia slope and should therefore run parallel to it.

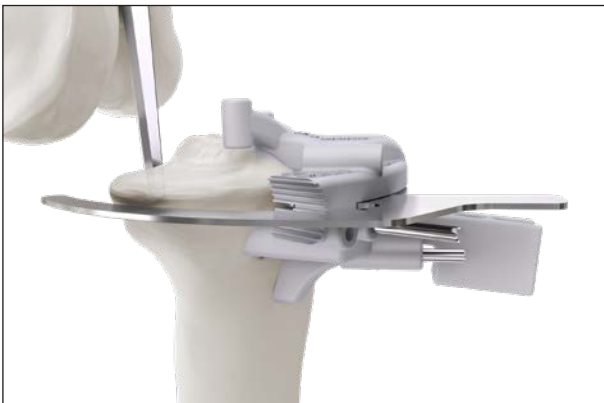

Fig. 13

3. Insert the reference plate into the sawing slit. The resection plane, which is indicated by the tip of the reference plate, can be reconciled with the resection plane on the bone model.

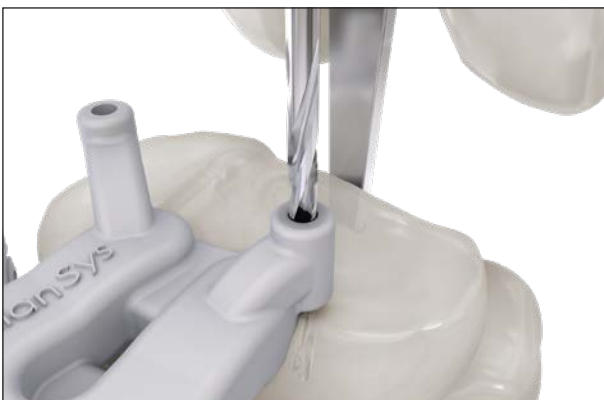

Fig. 14

The planning of the SuMisura tibia cutting guide makes it possible to define the rotation of the prosthesis plateau on the tibia resection surface. Two vertical pin guides on the cutting guide over the joint surface define the planned tibia plateau rotation. Two 15–20 mm deep holes are drilled through the two vertical drilling guides with the 3.2 mm drill bit.

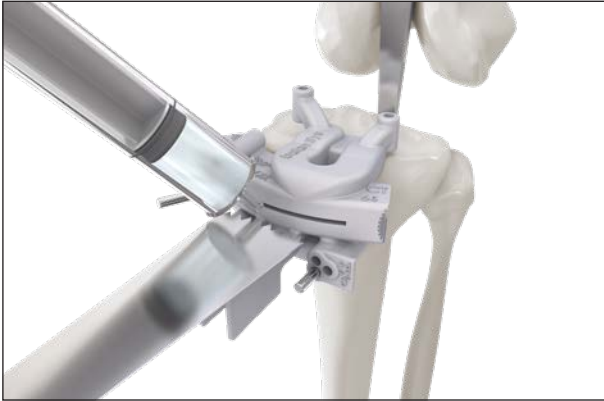

Fig. 15

Resect the tibia with a 1.27 mm saw blade through the sawing slit.

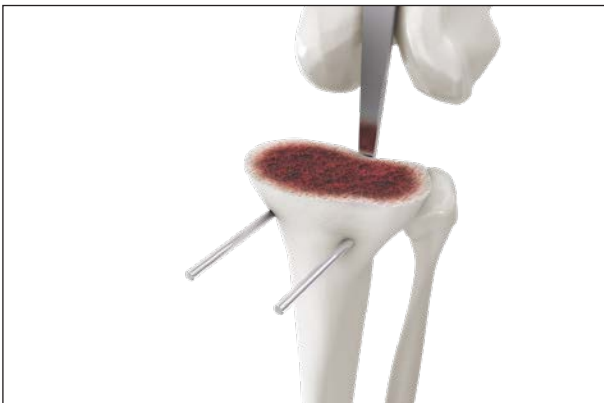

Fig. 16

When removing the tibia cutting guide, remove only the oblique pin. For possible secondary resection, the pins remain in position «0» in the bone.

Then remove the tibia head resectate. The tibia resectate must be compared with the tibia bone model. They must be identical.

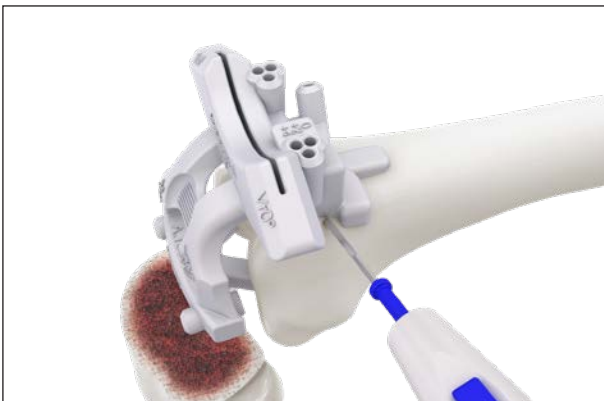

Fig. 17

5.2 Femur resection

Positioning of the knee in 90° flexion, holding away of the extensor system and provisional placement of the femur cutting guide. Mark the provisional position of the T-bar and the support feet with an electrocautery.

Remark

Several sites of the osteophyte are used as reference for correct positioning of the femur cutting guide, and the osteophytes may be removed only after the resection has been performed.

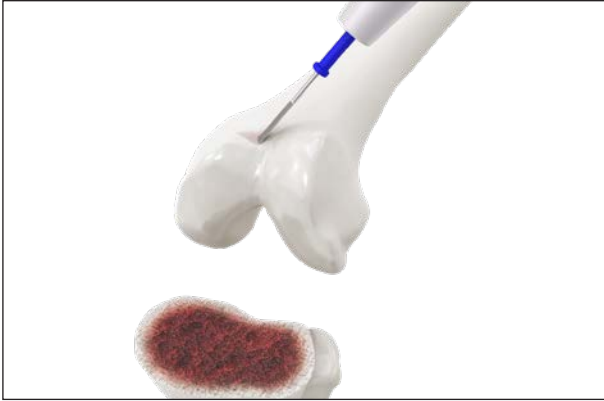

Fig. 18

After removal of the cutting guide, tissue removal in the region of the marked bearing surfaces for the T-bar and cartilage removal in the region of the support feet at the trochlear osteophytes.



Fig. 19

Renewed placement of the cutting guides with maximally precise positioning of the T-bar and on the support feet at the trochlear osteophytes.

Marking of the support feet in the joint surfaces.

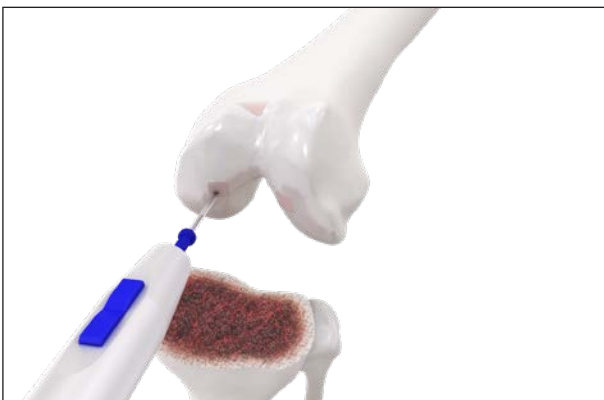

Fig. 20

Removal of the cutting guide. Cartilage removal and exposure of the marked bearing surfaces for the support feet in the joint surfaces.

Remark

Until the final positioning of the cutting guide, in many cases several repeat additional cleanings are necessary, followed by a check with the cutting guide in place. When the bearing surfaces of the T-bar and support feet are no longer compromised by soft tissue or cartilage, fine cleaning of the bearing surfaces with a wet compress is to be performed.

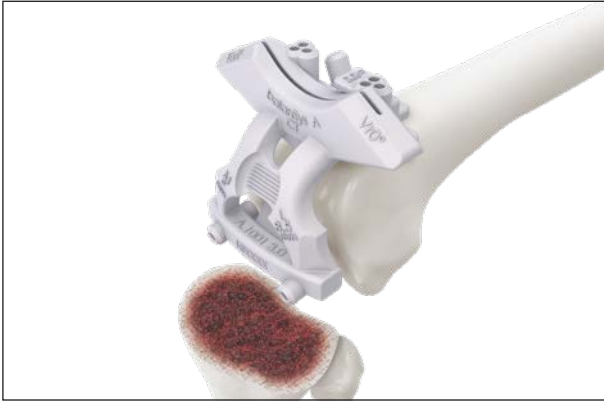

Fig. 21

Position the femur cutting guides on the prepared bearing surfaces.

Exact placement on clean bearing surfaces is indicated by the cutting guide snapping into place.

Complete placement of the T-bars and the support feet in the joint surface, then check the position of the support feet at the trochlear osteophytes.

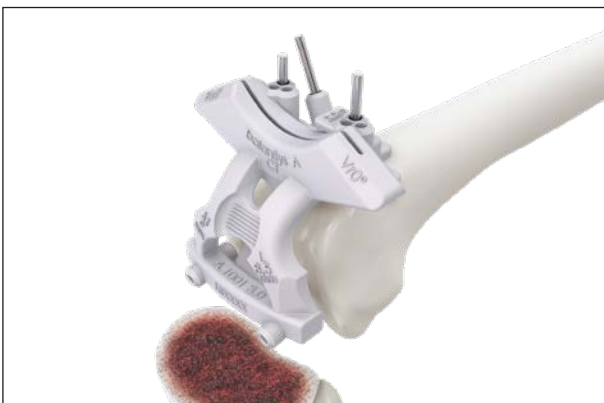

Fig. 22

When the femur cutting guide is exactly and definitely placed, fix it with two parallel pins in position «0» and with one oblique pin.

Remark

To prevent unintentional moving of the cutting guide when inserting the pins, the holes must always be pre-drilled with a 3.2 mm drill bit, or special drilling pins with a sharp tip and thread tap should be used. In either method, axially correct drilling is to be ensured.

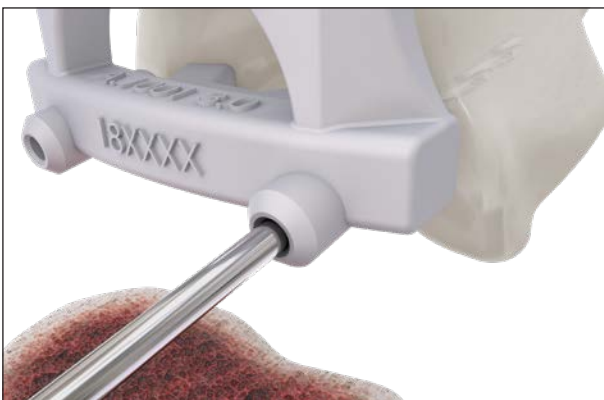

Fig. 23

Drill the holes for distal pin fixation. These holes are simultaneously the receiving holes for the 4-in-1 cutting block to be used later, and also define the rotation of the femur shield. Drill as accurately as possible in axial direction.

Remark

Make sure to drill the holes at least 35 mm deep.

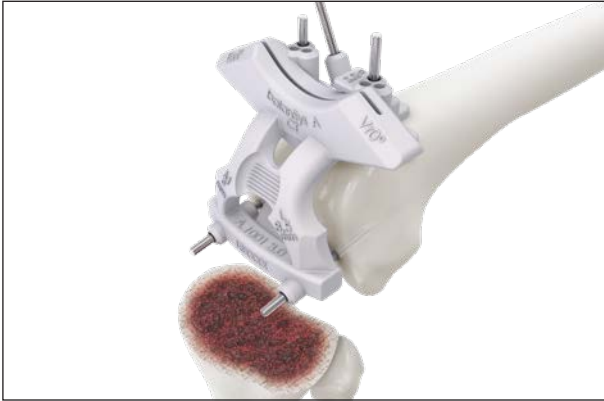

Fig. 24

Distal fixation of the femur cutting guide with two pins.



Fig. 25

Insert the reference plate into the sawing slit to check the resection plane.

The resection plane, which is indicated by the tip of the reference plate, can be verified with the resection plane on the bone model: the depth of the trochlea resection serves as reference, as does the resection plane in the region of the marginal osteophytes at the femoral condyles.



Fig. 26

Remove one distal pin and perform resection with a 1.27 mm saw blade on the appropriate side.



Fig. 27

Re-insert the pin, remove the pin on the contralateral side and complete the resection.

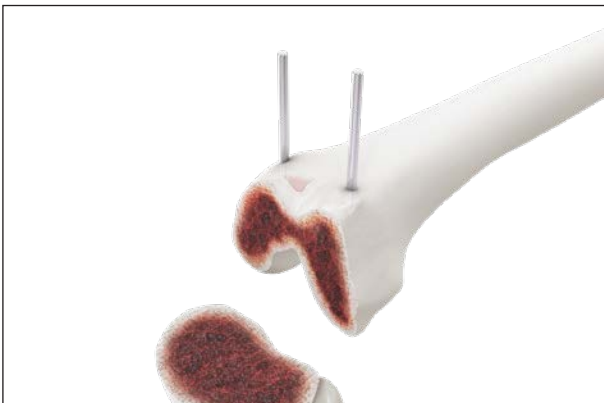

Fig. 28

Remove the oblique pin and remove the femur cutting guide.

After removal, leave both pins in position «0» for any secondary resection which may be necessary in the bone.

Compare the femur resectate with the femur bone model. They must be identical.




Fig. 29

5.3 Checking the extension gap

Check the extension gap by placement of the spacer block for the femur with the corresponding spacer block for the tibia. The extension gap should be balanced M-L with the leg fully extended.



Fig. 30

Check the mechanical axis and medial and lateral stability as well as extension ability. If the conditions are unfavorable, corrective resection can be performed on the distal femur or the proximal tibia.

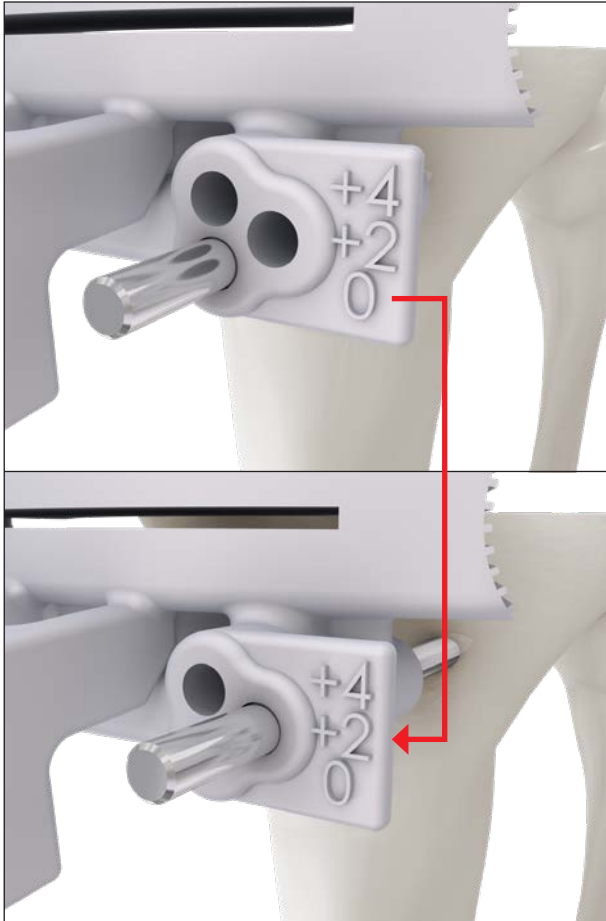


Fig. 31

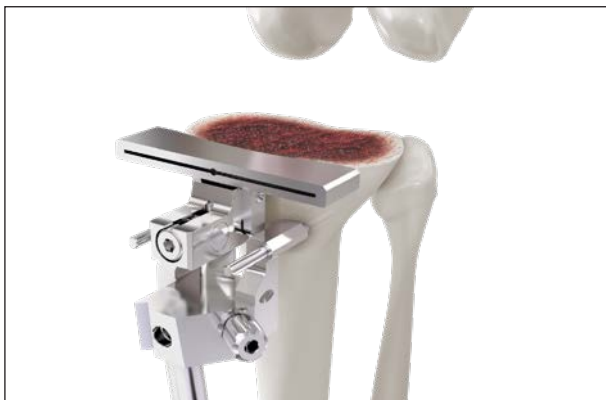

Fig. 32

5.4 Secondary resection (optional)

If a secondary resection is desired, move the cutting guide to the corresponding plane (+2 mm or +4 mm) and perform the resection as described above.

Tibia secondary resection

With the securing pins of the SuMisura cutting guide on the tibia, not only the SuMisura tibia cutting guide but also the conventional tibia reference system (TRS) can be used.

However, the conventional TRS cutting guide must be adjusted according to the primary resection: slope, height. Use a reference plate to align the cutting guide and resection surface with each other.

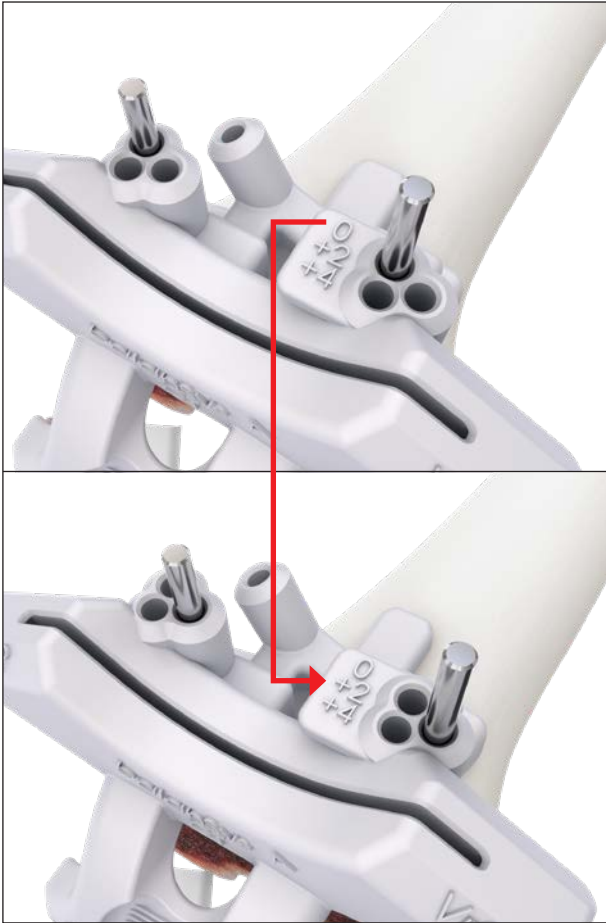


Fig. 33

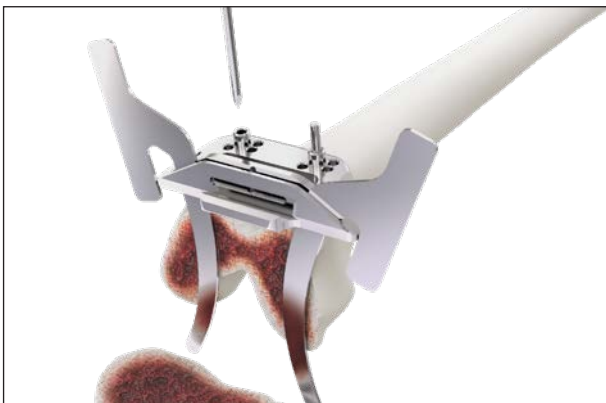

Fig. 34

Femoral secondary resection

With the securing pins of the SuMisura cutting guide on the femur, **only** the SuMisura femur cutting guide may be used.

Remark

The distal femur cutting guide of the conventional instrumentation has a different pin alignment and must not be used with the securing pins of the SuMisura femur cutting guide.

If secondary resection is performed with the conventional femur cutting guide, reference to the femur resection is established using two reference plates in the sawing slit of the gauge and the femur cutting guide is fixed with two new pins.

6. Finalizing

Perform the remaining steps according to the surgical technique balanSys BICONDYLAR SMarT.

As the next step, perform the anterior and posterior femur resection with the bevel cuts using the selected 4-in-1 cutting block.

All surgical steps downstream of the use of the patient-specific cutting guide are identical for all balanSys BICONDYLAR SMarT surgical techniques.

7. Addendum on MRI cutting blocks



With the MRI-based method, the planning and the cutting blocks are referenced to possibly present residual cartilage.

This should therefore not be removed, in contrast to the CT-based method, for which referencing is to the subchondral bone.

8. Instruments



Item no.	Description
71.34.8002	SuMisura for balanSys BICONDYLAR SMarT CT Set Tibia and Femur – Option Central



Item no.	Description
71.34.8003	SuMisura for balanSys BICONDYLAR SMarT CT Set Tibia and Femur – Option Edge



Item no.	Description
71.34.8004	SuMisura for balanSys BICONDYLAR SMarT MRI Set Tibia and Femur

Manufacturer



Distributed by



Australia	Mathys Orthopaedics Pty Ltd Lane Cove West, NSW 2066 Tel: +61 2 9417 9200 info.au@mathysmedical.com	Italy	Mathys Ortopedia S.r.l. 20141 Milan Tel: +39 02 5354 2305 info.it@mathysmedical.com
Austria	Mathys Orthopädie GmbH 2351 Wiener Neudorf Tel: +43 2236 860 999 info.at@mathysmedical.com	Japan	Mathys KK Tokyo 108-0075 Tel: +81 3 3474 6900 info.jp@mathysmedical.com
Belgium	Mathys Orthopaedics Belux N.V.-S.A. 3001 Leuven Tel: +32 16 38 81 20 info.be@mathysmedical.com	New Zealand	Mathys Ltd. Auckland Tel: +64 9 478 39 00 info.nz@mathysmedical.com
France	Mathys Orthopédie S.A.S 63360 Gerzat Tel: +33 4 73 23 95 95 info.fr@mathysmedical.com	Netherlands	Mathys Orthopaedics B.V. 3001 Leuven Tel: +31 88 1300 500 info.nl@mathysmedical.com
Germany	Mathys Orthopädie GmbH «Centre of Excellence Sales» Bochum 44809 Bochum Tel: +49 234 588 59 0 sales.de@mathysmedical.com «Centre of Excellence Ceramics» Mörsdorf 07646 Mörsdorf/Thür. Tel: +49 364 284 94 0 info.de@mathysmedical.com «Centre of Excellence Production» Hermsdorf 07629 Hermsdorf Tel: +49 364 284 94 110 info.de@mathysmedical.com	P. R. China	Mathys (Shanghai) Medical Device Trading Co., Ltd Shanghai, 200041 Tel: +86 21 6170 2655 info.cn@mathysmedical.com
		Switzerland	Mathys (Schweiz) GmbH 2544 Bettlach Tel: +41 32 644 1 458 info@mathysmedical.com
		United Kingdom	Mathys Orthopaedics Ltd Alton, Hampshire GU34 2QL Tel: +44 8450 580 938 info.uk@mathysmedical.com

Local Marketing Partners in over 30 countries worldwide ...